



PRESENTING CLINICAL SIGNS

DATE History: Echo in 2020 showed possible HCM. Possible grade II/VI murmur. Asymptomatic. Pre-anesthetic evaluation.

12/1/22

ECHOCARDIOGRAPHIC FINDINGS

PERFORMED BY: 2D, M-mode, and Doppler study.

Dr. Meredith Swart Left atrial size is normal. The mitral valve is normal. Left ventricular wall thickness is normal. Left ventricular internal dimensions are normal. Left ventricular systolic function is hyperdynamic. The aorta and aortic valve are normal. Right atrial and right ventricular dimensions are normal. The tricuspid valve is normal. The pulmonary artery and pulmonic valve are normal. No shunting lesions are visualized. No pericardial effusion or cardiac masses are seen.

INTERPRETED BY

Keith Blass, DVM,
MS, DACVIM
(Cardiology)

LA/Ao – 1.18
IVSd – 5.0 mm
LVPWd – 5.0 mm
LVIDd – 13.2 mm
LVIDs – 5.2 mm
FS – 60.6%
LVOT – 1.05 m/s
RVOT – 1.36 m/s

PATIENT

Kitty Ramirez

SPECIES

Feline

ASSESSMENT/RECOMMENDATIONS

Normal echocardiogram

This examination demonstrates no evidence of structural heart disease. As such, Kitty's cardiovascular risk for general anesthesia appears to be low, and there are no contraindications to the use of any specific anesthetic agents.

BREED

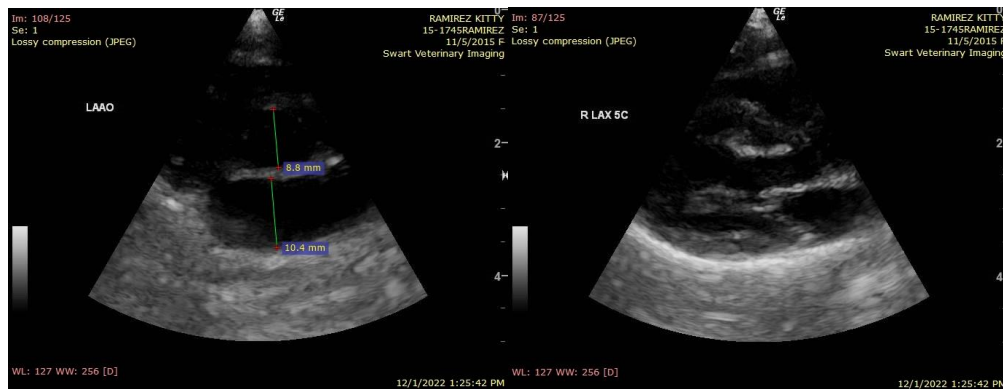
DSH

No therapy is recommended based on this exam.

SEX

A recheck echocardiogram is recommended if the characteristics of Kitty's murmur change, or if other new physical exam and/or clinical abnormalities suggestive of cardiac dysfunction develop.

MN



AGE

7 y

WEIGHT

9.4 lb

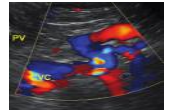
HOSPITAL NAME

Swart Veterinary
Imaging

The information and recommendations provided are based on the images presented by the referring veterinarian. No evaluation can be communicated regarding pathology that was not visible in the image/video clips provided.

REFERRING VET

Dr. Swart



DATE

Thank you for this referral. If the clinical or image interpretation does not parallel your findings or if I can be of any further assistance please contact me.

12/1/22

PERFORMED BY:

Keith Blass, DVM, MS, DACVIM (Cardiology)
KeithBlass@gmail.com
631-804-5754

Dr. Meredith Swart

INTERPRETED BY

Keith Blass, DVM,
MS, DACVIM
(Cardiology)

PATIENT

Kitty Ramirez

SPECIES

Feline

BREED

DSH

SEX

MN

AGE

7 y

WEIGHT

9.4 lb

HOSPITAL NAME

Swart Veterinary
Imaging

REFERRING VET

Dr. Swart